

Age changes in the position of mandibular foramen related to the occlusal plane and other mandibular parameters on orthopantomograms among 7-11 years old ages among Sulaimani children



Sulaimani Dental Journal

*Dler Abdulrahman Mohammed**

* B.D.S, M.Sc (Anatomy).
Department of Basic Sciences,
School of Dentistry, Faculty of
Medical Science, University of
Sulaimani, Iraq.

Abstract

Objectives: Main objective of this study was to estimate gender and age changes in the position of MF in relation to the occlusal plane among boys and girls aged 7 to 11 years old, also to record the distance between MF with each of the anterior border of ramus (AB), posterior border of ramus (PB), and the inferior border of ramus (IB) near the mandibular angle. Another aim was to find a correlation between the gonial angle (GA) and other mandibular ramus parameters.

Materials and Methods: 200 normal panoramic radiographs belong to 100 boys and 100 girls between 7-11 years old age, were included in this study. Radiographs collected from different sources. Seven points; four planes; four lines; and one angle were traced on the right side of the radiographs. AutoCAD and Photoshop programs were used to measure distances from MF to each of the occlusal planes; AB; PB, and IB. also GA were measured. These measuring were assessed and compared in different age and sex groups to determine the relative position of MF to the occlusal plane and other parameters.

Results: These results showed statistically significant increasing in all parameters in relation to the aging process and both sexes (P value<0.5). Boys had higher measurements than girls in all parameters except for the distance between MF and occlusal plane. GA showed a negative correlation with aging in both sexes.

Conclusions: It is concluded that IANB anesthesia is well done if the dental needle inserted below and above the occlusal plane in 7-9 and 10-11 years old boys respectively. While it should be inserted below and above the occlusal plane in 7-8 and 9-11 years old girls respectively. GA has a negative correlation with the occlusal plane and other mandibular parameters (P value<0.5). The relation between MF distance to other mandibular parameters and with advancing age in both sexes were statistically significant (P value<0.5).

Correspondence to;

Dr. Dler A. Mohammed
drdiler@yahoo.com

Received: August, 2015

Accepted: October, 2015

Published: December, 2015

Keywords: mandibular foramen, panoramic radiograph, occlusal plane.

Cite this article as:

Mohammed DA. Age changes in the position of mandibular foramen related to the occlusal plane and other mandibular parameters on orthopantomograms among 7-11 years old ages among Sulaimani children. Sulaimani Dent J. 2015;2(2):94-100.

Introduction:

Mandible is a flat, dense, compact bone; the thickest part is located on the oblique line and mylohyoid line, and this is the place of maximum stress⁽¹⁾. Quadrangular shape ramus that has two surfaces and two laminae consisting the posterior part of the mandible. The body of the mandible is forming its anterior part with the mandibular angle between them^(1,2). A bony plate called lingula located at the medial surface of ramus just anterior to MF that attached to the sphenomandibular ligament^(3,4). Lingula can be palpated through the oral mucosa, at this point dentist can insert dental needle while performing IANB anesthesia⁽⁵⁾. The superior surface of ramus has anterior coronoid and posterior condylar processes with a mandibular notch between them.

Mandibular foramen transmits neurovascular bundles; inferior alveolar nerve, a branch of mandibular division of the trigeminal nerve and inferior alveolar artery a branch of a maxillary artery that supplies the lower teeth, as well as the lower lip and some skin on the lower face⁽⁶⁾. Studies have shown racial differences in the anatomy of the mandible. In the variety of studies, the mandibular and mental foramen are often chosen as reference points because of their stable relation with the base of the mandible⁽⁷⁾. Morphological studies had been done of the facial skeleton in different populations for identification of the human remains⁽⁸⁾. Dimorphism has been observed between different mandibles in different age and gender groups but it exist to a lesser extent, and this finding may affect MF position in relation to the occlusal plane⁽⁹⁾.

Age and gender factors have an effect on the growth of craniofacial complex and remodeling process of the mandible that occur from the prenatal period until senility, which intern affect many parameters such as MF, mandibular canal, gonial angle and other parameters⁽¹⁰⁾.

Many studies have been done on the position of MF in relation to the occlusal plane and other parameters, but till now a day exact location is not fully understood⁽¹¹⁾. The assessment of the correct location of MF has a vital role in the diagnosis of some oral lesions, maxillofacial surgery planning, and other various dental procedures⁽¹²⁾. The location of the inferior alveolar canal is of utmost importance when dental implants are the treatment of choice and during other dental conservative procedures. Considerable changes occur in the position of MF in relation to occlusal plane with the child developing, and this should be taken in a mind to obtain successful INAB anesthesia. Some authors state the changes in parameters of facial bones and dental structures to the ethnic origins⁽¹³⁾. It was stated that the position of MF located below the occlusal plane regarding deciduous mandibular teeth⁽¹⁴⁾. Other authors suggested the location of MF at or above the occlusal plane in primary dentition^(15,16). Efficient, adequate and safe anesthesia is an important issue and fundamental in the practice of dentistry for both the patient and dental professional. This is may be easily and simply be done in the maxilla, however relating to the mandible may have some difficulty, because of the greater density of the mandibular alveolar bone, limited access to the inferior alveolar nerve, marked anatomical variations, in addition to the need for deeper needle penetration into the soft tissue⁽¹⁷⁾. Inadequate knowledge of the anatomy that lead to improper localization of mandibular canal, technical errors, anxious or uncooperative patients, infection at the site of injection, accessory innervations, and inexperienced dentist are important factors of failure anesthesia⁽¹⁸⁾. Some patients prefer some dentists according to their experience and their ability to offer adequate painless dental treatments⁽¹⁹⁾.

The goal of this paper was to find the age and gender changes in the position of MF in relation to the occlusal plane on orthopantomograms among the Sulaimani children aged 7-11 years. Another objective was to find a relation between MF with an anterior, posterior, and inferior border of the mandibular ramus. Also to estimate the changes in the internal mandibular gonial angle records.

Materials and Methods:

The study was approved by the Committee of ethic in the School of Dentistry/ Faculty of Medical Sciences/ University of Sulaimani. There were 200 orthopantomograms from both genders (100 boys and 100 girls). Subjects were divided into five age groups with 20 images for each group. Ages ranged between seven and eleven years as shown in Table (1).

Panoramic radiographs were previously made and acquired earlier on patients pool who presented to the oral radiology clinic of the school of dentistry, the University of Sulaimani, peeramerd dental hospital, and some other privet dental clinics with a specialty in maxillofacial and dental radiology. The subjects came for various treatment needs such as initial screening or oral surgery i-e not chosen only for this study. The study was prospective, and data collection was extended from 2010 to January 2015. Planmeca Dimax3 Digital X-Ray machine Finland, and Pax I Vatech Korean were used to take the panoramic radiographs from the subjects. Appropriate exposure factors were selected according to the user manual of the machine. The magnification factors reported by the manufacturers were 1.2 (Real value = estimatedvalue/ 1.2).

Inclusion criteria:

The criteria that every individual had to meet to be involved in this investigation are as follow:

Table 1: Age and gender groups, number and percentage distribution of study samples.

| Groups | Age (years) | Number | |
|--------------------|-------------|-------------------|------|
| 1 | 7 | 20 Boys, 20 Girls | %20 |
| 2 | 8 | 20 Boys, 20 Girls | %20 |
| 3 | 9 | 20 Boys, 20 Girls | %20 |
| 4 | 10 | 20 Boys, 20 Girls | %20 |
| 5 | 11 | 20 Boys, 20 Girls | %20 |
| Total cases | | 200 | %100 |

All participants were clinically in generally healthy condition, acceptable density, and contrast images, and the presence of all posterior teeth at the studied side of the mandible.

Exclusion criteria:

with unclear anatomical landmarks, patients with a history of trauma or any congenital deformity of the jaw, or whom under orthodontic treatments, and absence of posterior teeth were excluded from the study.

Since the MF usually have a symmetrical configuration, even among different ethnicities and also there is no right and left side dominance in the ramus and MF; therefore only the right side of the mandible was traced^(5,20-22).

Auto CAD and Photoshop programs were used to draw the points and lines at the specific area as well as for measuring gonial angles. All the measurements were recorded in millimeter. For each of the radiographs, seven points were traced on the radiographs as follow and shown in figure (1).

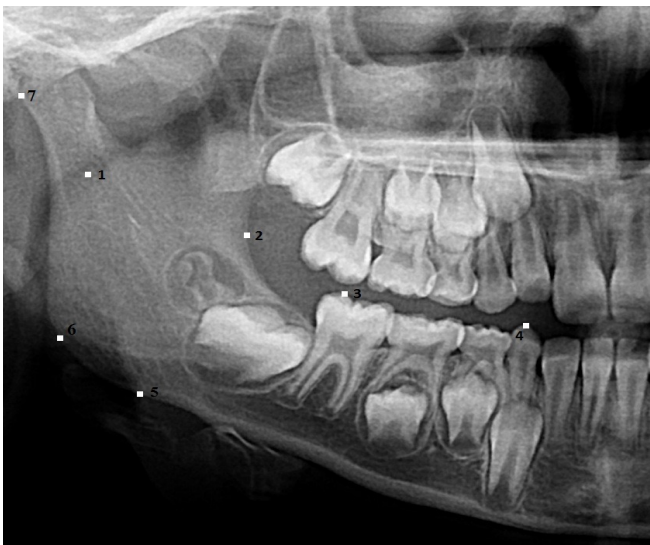


Figure 1: Points of the study drawn on the radiograph.

Point 1: In the middle of MF.

Point 2: At the anterior border of the ramus between coronoid process and base of the mandible.

Point 3: Prominent point on the canine tooth.

Point 4: Point on the occlusal surface of most fully erupted posterior tooth.

Point 5: Inferior border of mandible near the angle.

Point 6: Prominent point posterior to the mandibular angle.

Point 7: Posterior point on condyle.

Also, four planes were traced as follow and shown in figure (2):

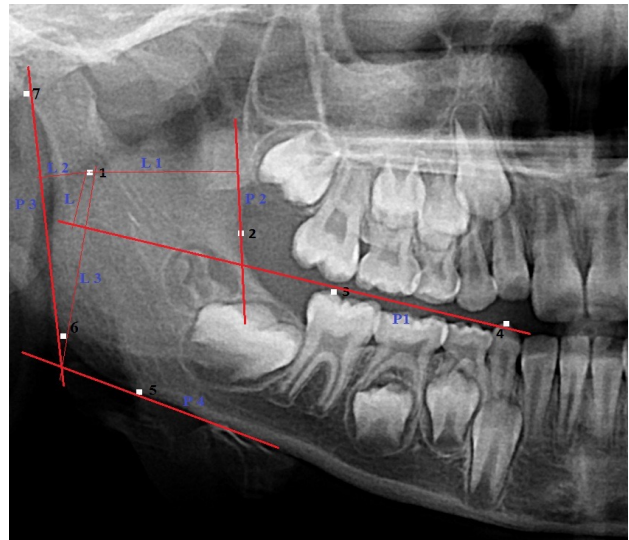


Figure 2: Planes and lines of the study.

P1 (Plane 1): Occlusal plane connects points 3 and 4.

P2 (Plane 2): a Vertical line was drawn to point 2 from upper part of anterior ramus border to its lower part.

P3 (Plane 3): line drawing at the posterior border of the ramus connecting point 6 and point 7.

P4 (Plane 4): Mandibular plane tangent to the point 5 and inferior mandibular border or mandibular base.

Four different lines were drawn from the MF and the mentioned planes as follow:

L: Perpendicular line from point 1 to plane 1.

L1: Perpendicular line from point 1 to plane 2.

L2: Perpendicular line from point 1 to plane 3.

L3: Perpendicular line from point 1 to plane 4.

Lastly, the internal angle between plane 3 and plane 4 were calculated which indicates the internal mandibular gonial angle.

Statgraphics plus 40 programs were used for statistical analysis of the means and variables, the correlation between different variables were assessed in simple and multiple linear regression analysis. T-Test was applied to find the correlation between the means, P-value equal or less than (0.05) regarded statistically as a significant at 95% confident level. The means, and the standard deviation of linear and angular measurements were analyzed in (ANOVA).

Results:

The mean distances for all measurements were performed on the side of the mandible on the selected orthopantogram images. The mean distances from the MF to the occlusal plane (L), standard deviation (S.D), and the P value among the boy and girl age

groups were shown in (Table 2). The mean distances from the mandibular foramen to the: anterior border (L1); posterior border (L2); inferior border of the mandibular ramus (L3) among the different age and gender groups were shown in (Table 3). The mean measurements of gonial angle within boys and girls age groups were shown in (Table 4).

Overall recorded measurements with the exception of the gonial angle records, the measurements were increased significantly with the age and in both sexes. Boys had higher measurements than girls except for the distance between mandibular foramen and occlusal plane (P value less than 0.05). Gonial angle decreased with advancing age; statistical analysis showed

Table 2: Mean distance (in millimeters) between point 1 (mandibular foramen) and occlusal plane (L) in different age and gender groups (mean values on the right the side of mandible).

| Measurements | | | L in boys | | L in girls | |
|-----------------------------------|------------------------------|-------------------------------|---------------|------|---------------|------|
| Age | Number of observation (boys) | Number of observation (Girls) | Means | S.D | Means | S.D |
| 7 | 20 | 20 | -2.53 | 0.7 | -1.75 | 0.98 |
| 8 | 20 | 20 | -1.61 | 0.51 | -1.21 | 0.49 |
| 9 | 20 | 20 | -0.46 | 0.35 | 0.92 | 0.11 |
| 10 | 20 | 20 | 1.37 | 0.6 | 1.82 | 0.3 |
| 11 | 20 | 20 | 1.86 | 0.74 | 2.2 | 1.4 |
| Significant levels ANOVA analysis | | | P value <0.05 | | P value <0.04 | |

Table 3: Means (in millimeters) of the distances from mandibular foramen to each of the anterior ramus boarder (L1), posterior ramus boarder (L2), and inferior ramus boarder (L3) in different age and gender groups.

| | Age | 7 | | 8 | | 9 | | 10 | | 11 | |
|----|---------|--------|-------|--------|-------|-------|-------|-------|-------|-------|-------|
| | Gender | Boys | Girls | Boys | Girls | Boys | Girls | Boys | Girls | Boys | Girls |
| L1 | Mean | 13.25 | 12.25 | 13.55 | 12.95 | 13.59 | 13.02 | 13.64 | 13.06 | 14.01 | 13.37 |
| | S.D | 2.32 | 1.41 | 1.09 | 1.6 | 2.6 | 1.3 | 1.94 | 1.13 | 3 | 2.1 |
| | P value | 0.0001 | | 0.0003 | | 0.004 | | 0.003 | | 0.006 | |
| L2 | Mean | 11.01 | 10.21 | 11.4 | 10.6 | 11.5 | 10.8 | 12.62 | 11.9 | 13.3 | 12.4 |
| | S.D | 2.21 | 1.8 | 2.03 | 3.1 | 2.8 | 2.7 | 1.56 | 1.98 | 2.56 | 1.74 |
| | P value | 0.0001 | | 0.02 | | 0 | | 0.005 | | 0.04 | |
| L3 | Mean | 19.1 | 17.02 | 19.7 | 17.8 | 20.1 | 19.1 | 20.8 | 19.9 | 21 | 20.3 |
| | S.D | 6.8 | 1.9 | 1.5 | 0.25 | 1.06 | 4.3 | 0.95 | 1.3 | 1.8 | 1.3 |
| | P value | 0.000 | | 0.002 | | 0.01 | | 0.005 | | 0.01 | |

Table 4: Means (in millimeters) of internal gonial angle (GA) in different age and gender groups.

| Measurements | | | G.A in boys | | G.A in girls | |
|-----------------------------------|------------------------------|-------------------------------|----------------|------|---------------|------|
| Age | Number of observation (boys) | Number of observation (Girls) | Means | S.D | Means | S.D |
| 7 | 20 | 20 | 122.2 | 1.19 | 125.3 | 2.74 |
| 8 | 20 | 20 | 120.5 | 3.7 | 124.1 | 2.1 |
| 9 | 20 | 20 | 120 | 1.4 | 123.3 | 2.3 |
| 10 | 20 | 20 | 119.1 | 2.9 | 122 | 2.6 |
| 11 | 20 | 20 | 118.2 | 1.3 | 121.1 | 3.4 |
| Significant levels ANOVA analysis | | | P value <0.001 | | P value <0.05 | |

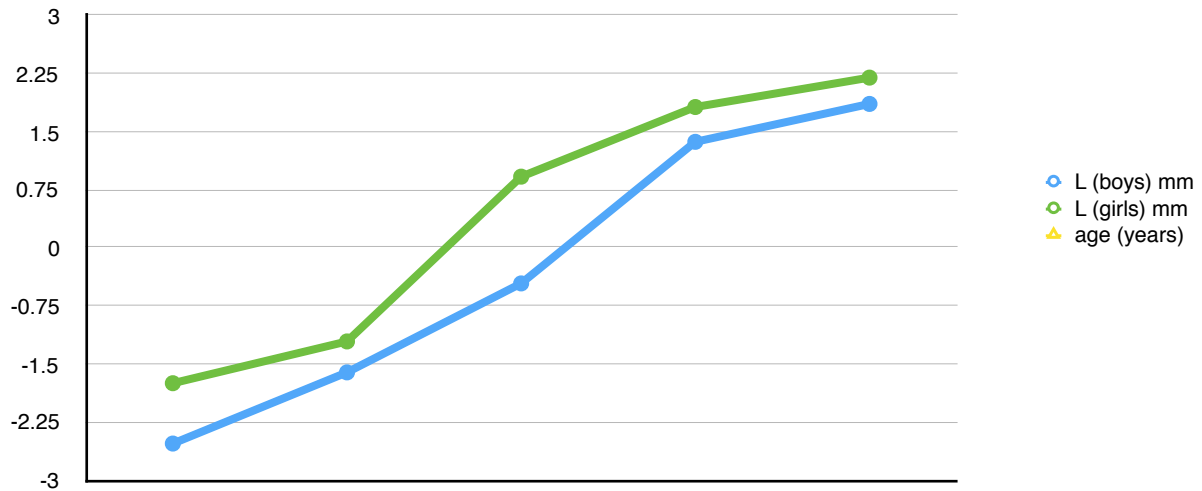


Figure 3: Correlation between age (horizontal lines) in the year, and L (vertical lines) in millimeter.

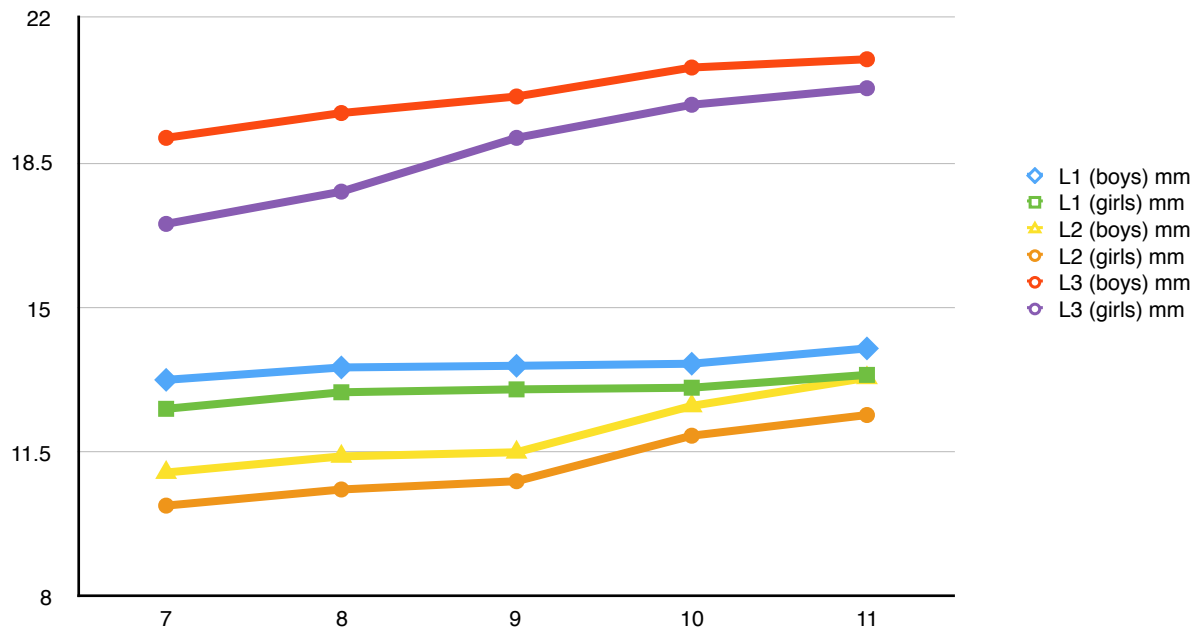


Figure (4): Correlation between age (horizontal lines) in year, with L1, L2, and L3 (vertical lines) in millimeter in both sexes.

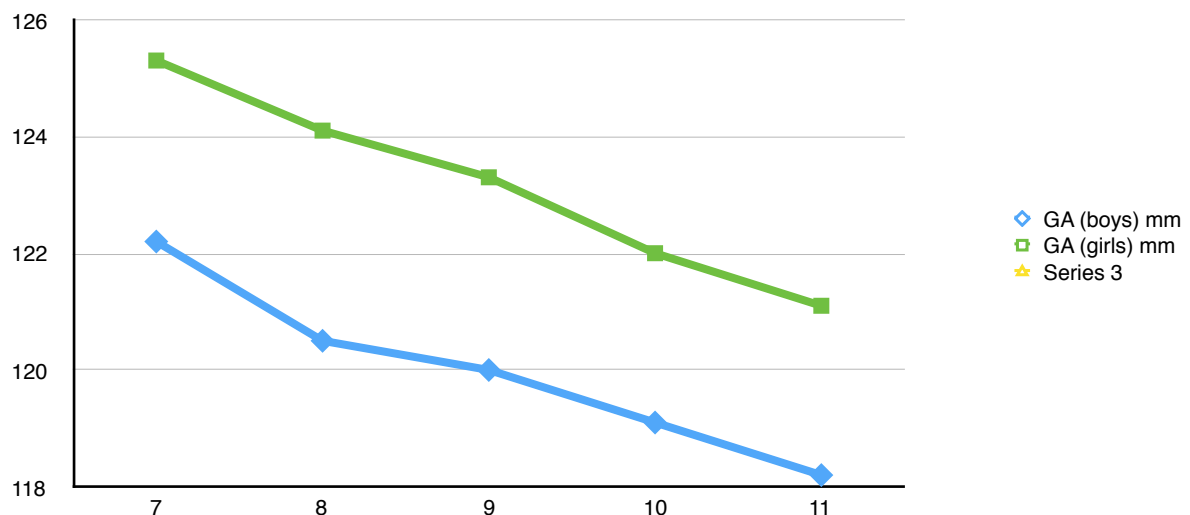


Figure (5): Correlation between age (horizontal line) in year, with GA (Vertical line) in millimeter in both sexes.

negative correlation between distance from mandibular foramen to various mandibular ramus parameters and the degree of gonial angle (P value less than 0.05).

Discussion:

The assessment of the MF is of considerable importance for surgery planning, endodontic treatments, and lesions diagnosis. Incorrect estimations of its location might be the explanation to the unsuccessful anesthesia of the IANB. The eruption and exfoliation of the teeth have an important role in the bone remodeling and apposition especially on the anterior border of the ramus and this may change the MF position and helps the proper IANB anesthetic technique that is required for painless calm fashion treatment field. Positioning the dental needle too much above or below the MF may result in failure IANB⁽²³⁾.

Authors stated the efficacy of panoramic radiographs for the detection of intraosseous lesions in asymptomatic patients as well as for determination of various jaw borders and they found that panoramic radiographs have a vital role especially in the treatment of pediatric dental patients⁽²⁴⁾. Panoramic radiography produces a single image of maxillary and mandibular arches, it requires less radiation, more economic, easier and saves time; hence it is preferred to periapical images. Studies showed that panoramic radiograph readings may substitute for full-mouth periapical radiographic evaluation⁽²⁵⁾. There is no significant difference between panoramic radiographs and oblique cephalometric radiographs regarding discerning the MF location⁽¹¹⁾. Panoramic imaging is widely used to evaluate the jaws when planning implant surgeries and for other purposes. The image quality of panoramic radiography can be increased using digital panoramic radiography and by using software programs.

Since the panoramic radiographs provide reasonable visualization of the anatomical structures in the oral region, we used panoramic radiographs for studying the anatomic location and relation of MF with other mandibular parameters and the changes that may occur with aging and also between genders. Various other studies have used similar methods to study the position of MF and its relation to other bony landmarks⁽²⁸⁾. Results of this study showed significant changes in the distance between MF and the occlusal plane with aging process, also reveals statistically significant differences between gender age groups $P < 0.05$ regarding this distance (figure 3). Location of MF changes vertically and horizontally with both sex and age factors, and this is well agreed with some authors^(15,27). While disagreeing with other researchers⁽¹⁵⁾. Bone remodeling at the anterior mandibular ramus, tooth eruption, and exfoliation may play an important role in changing the level and distance of MF from the occlusal plane and other parameters.

Finding of this paper revealed that MF located below the occlusal plane in 7,8,9 years old age boys and 7,8 years old age girls, while it's located slightly above the occlusal plane in 9 years age girls, and this is

may be due to prepubertal growth in girls before boys. At the age of 10-11 years, the MF become more upward positioned in relation to the occlusal plane and become at or above the occlusal plane as shown in figure (3). Only within very small child groups the MF stay at the level of the occlusal plane or slightly below, this is may be due to the body characteristic, hormonal and genetic factors. MF and its contents influence the growth of the mandible while development of mandible may not have a significant role in the MF position⁽²⁶⁾.

The results of the present study showed that the distance of MF to the L1, L2, and L3 increases significantly with aging process and in both sexes as shown in figure (4). We found that the L1 was greater than L2 in both sexes in all age groups. Also, L3 increases significantly with aging, and the sex differences were significant within all measured parameters as shown in figure (4). Growth rate at the anterior border of ramus increases mainly during 9-12 years age while very little growth noticed at the posterior ramus during this time. This is may be due to that the growth spurt affects the anterior ramus more than the posterior ramus, and this result in more bone apposition at the anterior ramus boarder. Slight increasing in growth rate noticed at the posterior ramus border at 11-12 years age, this indicates that the posterior border of the ramus growth is more predictable and constant than anterior mandibular border⁽¹¹⁾.

The last finding of this study was negative correlation between the degree of internal gonial angle and the distance between MF with other mandibular parameters among the age and sex groups as shown in figure⁽⁵⁾. This well agrees with other finding⁽²⁴⁾. The reason of this may be due to changes in vertical and sagittal growth of mandibular condyle and more posterior downward inclination of occlusal plane, and this mostly happens during the transition from mixed to permanent dentitions⁽²⁹⁾.

Knowing the normal relationship and the anatomical variation of the maxillofacial structures for each patient is important for better treatment planning and hence help improve the predictability and outcome of surgical procedures and to avoid future complications. The main importance and applicant of the finding of this paper is that according to these results to perform adequate IANB anesthesia; it is preferable to insert the dental needle below and above the occlusal plane in 7-9 and 10-11 years old age boys respectively. While it should be inserted below and above the occlusal plane in 7-8 and 9-11 years old age girls respectively.

Acknowledgment:

I would like to introduce my great thanks and appreciation to all the staff of the X-ray departments of Peramerd Dental Hospital and school of Dentistry-Sulaimani University, for their help and support to me especially Dr. Ranj Adl and Dr. Khalid Hama Salih. I appreciate all the help to Dr. Nzar Muhammad for his help and effort in biostatistics greatly.

References:

1. M. Lipski 1, I.M. Tomaszewaska2, W. Lipaska3, G.J. Lis4, K.A. Tomaszewski. *The mandible and its foramen: Anatomy, anthropology, embryology and resulting clinical implications.* *Folia Morphol.* 2013;72, 4:285-292.
2. Ichim I, Swain M, Kieser JA. *Mandibular Biomechanics and Development of the human.* *Chin. J Dent Res.* 2006;85:638-642.
3. Radlanski RJ, Renz H, Klarkowski MC. *Prenatal development of the human mandible. 3D reconstructions, morphometry and bone remodelling pattern, sizes 12-117 mm CRL.* *J Dent.* 2003;4:166-170.
4. Fabian FM. *Observation of the position of the lingula in relation to the mandibular foramen and the mylohyoid groove.* *Ital J Anat Embryol.* 2006;111: 151-158.
5. Ennes JP, Medeiros RM. *Localization of mandibular foramen and clinical implication.* *Int J Morphol.* 2009;4:1305-1311.
6. Misch CE. *Applied anatomy for dental implants.* In: Misch CE, editor. *Contemporary Implant Dentistry.* 3rd ed. St Louis, Mo: Mosby; 2005. p. 495-500.
7. Kharoshah MAA, Almadani O, Ghaleb SS, Zaki MK, Fattah YAA. *Sexual dimorphism of the mandible in a modern Egyptian population.* *J Forensic Legal Med.* 2010;17:213-215.
8. Williams, P.L., Bannister, L.H., Berry, M., Collins, P., Dyson, M., Dussek, J.E. et al. *Gray's anatomy.* 38th ed. Churchill Livingstone; 2000. p. 576-7
9. Riepert, T., Drechsler, H., Schhile, B., Nafe and R. Mattern, 1996. *Estimation of sex on the basis of radiographs of calcaneus.* *Forensic Sci.* 1996;77:133-40.
10. Ashkenazi M, Taubman L. *Age associated changes of the mandibular foramen position in Anteroposterior dimension and of the mandibular angle in dry human mandibles.* *The Anatomical Record.* 2011;294:1319-25.
11. Afsar, A, Hasas D.A, Rossouw E, and Wood RE. *Radiographic Localization of mandibular anesthesia landmarks.* *Oral Surg Oral Med Oral Pathol Oral Radiol Endod.* 1998; 86:234-41.
12. Da Fontoura RA, Vasconcellos HA, Campos AE. *Morphologic basis for the intraoral vertical ramus osteotomy: Anatomic and radiographic localization of the mandibular foramen.* *J Oral Maxillofac Surg.* 2002;60:660-5
13. Bishara, S.E., E.M. Abdalla and B.J. Hoppens. *Cephalometric comparisons of dentofacial parameters between Egyptian and North American adolescents.* *Am. J. Orthod. Dentofacial. Orthop.* 1990;97: 413-421.
14. Olsen, N.H. *Anesthesia for the child patient.* *J. Am. Dent. Assoc.* 1956; 53: 548-55.
15. Benham, N. R. *The cephalometric position of the mandibular foramen with age.* *ASDC J. Dent. Child.* 1976;43: 233-237.
16. Erika Cvetko. *Bilateral anomalous high position of the mandibular foramen. A case report,* *Surg Radiol Anat.* 2013;10.
17. Nicholson ML. *A study of the position of the mandibular foramen in adult human mandible.* *Anat Rec.* 1985; 212:110-2.
18. McDonlad RE, Avery DR. *Local anesthesia for the child and adolescent.* 6th ed. St. Louis: Mosby; 1994. p. 294-306.
19. Madan GA, Madan SG, Madan AD. *Failure of inferior alveolar nerve block, exploring the alternatives.* *J Am Dent Assoc.* 2002;133:843-6.
20. Tsai, H.H. *Panoramic radiographic findings of the mandibular foramen from deciduous to early permanent dentition.* *J. Clin. Pediatr. Dent.* 2004;28: 215-219.
21. K. Thangavelu, R. Kannan, N. Senthil Kumar, E. Rethish, S. Sabitha, et al. *Significance of localization of mandibular foramen in an inferior alveolar nerve block.* *J Nat Sci Biol Med.* 2012;3:156-160.
22. Larheim TA, Svanaes DB, Johannessen S. *Reproducibility of radiographs with the orthopantomograph.* *Oral Surg Oral Med Oral Pathol.* 1984;58:736-41.
23. McKissock MD, Meyer RD. *Accessory innervation of the mandible, identification and anesthesia options.* *Gen Dent.* 2000;48:662-9.
24. Zeichner SJ, Ruttiman UE, Webber RL. *Panoramic radiography, efficacy in the assessment of intraosseous lesions of the face and jaws in asymptomatic patients.* *Radiology.* 1987;162:691-95.
25. R. Persson, S. Tzannetou, A. Feloutzis, U. Bragger, G. Persson, and N. Lang. *Comparison between panoramic and intra-oral radiographs for the assessment of alveolar bone levels in a periodontal maintenance population.* *J Clin Periodontol.* 2003;30:833-839.
26. Moss ML, Salentijn L. *The primary role of functional matrices in facial growth.* *Am J Orthod.* 1969;55: 566-77.
27. Kanno, C.M., J.A. de Oliveira, M. Cannon and A.A. Carvalho. *The mandibular lingulas position in children as a reference to inferior alveolar nerve block.* *J. Dent. Child.* 2005;72: 56-60.
28. Poonacha KS, Shigli AL, Indushekar KR. *Relative position of mandibular foramen in different age groups of children: a radiographic study.* *J Endod.* 2010;28:173-8.
29. Tsai, H.H. *Panoramic radiographic findings of the mandibular growth from deciduous dentition to early permanent dentition.* *J. Clin. Pediatr. Dent.* 2002; 26: 279-84.